



PATIENT

Milo Luckman

SPECIES

Feline

BREED

DSH

SEX

Male Neutered

AGE

9 years

WEIGHT

18.8lbs

INTERPRETED BY

Maggie Machen Lamy,
DVM, DACVIM
(Cardiology)

IMAGING PERFORMED BY

C. Zumpano, DVM

HOSPITAL NAME

Pikesville Animal
Hospital

REFERRING VET

Dr. Zumpano

INVOICE

47266

DATE

3/24/26

PRESENTING CLINICAL SIGNS

History: Grade 3/6 heart murmur. Asymptomatic. HR: 200-220bpm. BP: 130mmHg. Sedated with Gabapentin.

ECHOCARDIOGRAM FINDINGS

2D, m-mode, color flow and doppler imaging is available. The left ventricular wall is largely normal in dimension with regions of irregularity. There is a hyperechoic endocardium consistent with fibrosis. The left atrium is normal in size. Mild MV thickening with mild mitral regurgitation. No obvious systolic anterior motion of the MV is seen. The right atrium is normal in size. The right ventricle appears normal. No TR. Blood flow through both the LVOT and RVOT are normal in velocity. No effusions or cardiac tumors are identified.

CARDIAC CHART

FELINE CARDIAC PARAMETERS	BODY WEIGHT (kg)	HR (BPM)	IVSd (cm) (Moise, Pipers)	LVIDd (cm) (Moise, Pipers)	LVWd (cm) (Moise, Pipers)	FS (%)	EF (%)
NORMAL PARAMETER	-----	150-240	0.35-0.55	<2 (mean 1.5)	3.5-0.55	35-67	80-100
PATIENT	8.5	NM	0.52	1.6	0.50	47	90
FELINE CARDIAC PARAMETERS	LA/AO (Boon)	LA/AO HEART BASE (Swe) (Abbott)	LA 2D short axis Base view (cm) (Abbott)	LVOT VEL (m/s)	RVOT VEL (m/s)	E max (m/s)	
NORMAL	<1.5	<1.3	<1.2	<1.6	<1.3	<0.9	
PATIENT	1.5	.3	1.3	1.3	0.8	NM	

**Note: All measurements based upon multi-modal images and methods. An average value is reported.
Adapted from June Boon, Veterinary Echocardiography, 1998
Abbott J & MacLean H JVIM 2006;20: 111-119, Moise et al. Am J Vet Res 47:1476, 1986. Pipers et al. Am J Vet Res 40:882, 1979.*

INTERPRETATION OF THE FINDINGS & FURTHER RECOMMENDATIONS

The only cause of the murmur identified is mild mitral regurgitation. MR in cats is typically due to either MV dysplasia (abnormal morphology from birth) or secondary to abnormal valve motion (SAM/HOCM), neither of which are seen in this study. Mild MV thickening may represent early valve disease similar to as seen in dogs, and serial monitoring is advised particularly given the relatively large volume of regurgitation for a cat. The left atrium is normal, indicating low risk for clinical signs at this time. A baseline blood pressure is recommended.

Given a normal LA dimension, no medications are indicated and simple follow up is advised. Prognosis is guarded prior to assessing for progression.

The risk for general anesthesia is low, however heart rate stimulating drugs such as atropine, glycopyrrolate should be avoided unless medically necessary. Even without significant pathology, there is a mildly elevated risk for fluid overload in this patient. Judicious IV fluid use is



PATIENT

Milo Luckman

SPECIES

Feline

BREED

DSH

SEX

Male Neutered

AGE

9 years

WEIGHT

18.8lbs

INTERPRETED BY

Maggie Machen Lamy,
DVM, DACVIM
(Cardiology)

IMAGING PERFORMED BY

C. Zumpano, DVM

HOSPITAL NAME

Pikesville Animal
Hospital

REFERRING VET

Dr. Zumpano

INVOICE

47266

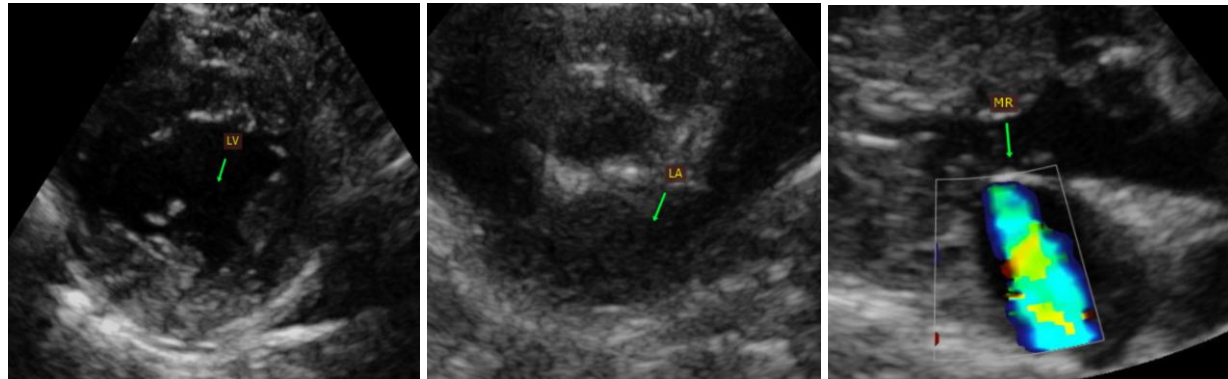
DATE

3/24/26

recommended. Risk for steroid use typically follows LA dilation, which in this case is low. That being said, any cat is at risk for unexpected intolerance and monitoring of RR/RE is recommended, particular during the initiation phase.

Recheck echocardiogram is recommended in 6-12 months, sooner if development of any clinical signs.

IMAGES



The information and recommendations provided are based on the images presented by the referring veterinarian. No evaluation can be communicated regarding pathology that was not visible in the image/video clips provided.

Thank you for this referral. This report was generated using transcription software, and minor dictation errors may be present. If the clinical or image interpretation does not parallel your findings or if I can be of any further assistance, please contact me.

Maggie Machen Lamy, DVM
Diplomate of the American College of Veterinary Internal Medicine (Cardiology)
info@sonopath.com